


Prevalence of xerophthalmia among malnourished children in rural Ethiopia

Daniel B. Moore, Wogen Shirefaw, Oren Tomkins-Netzer, Zebiba Eshete, Hila Netzer-Tomkins & Itay Ben-Zion

International Ophthalmology
The International Journal of Clinical
Ophthalmology and Visual Sciences

ISSN 0165-5701

Int Ophthalmol
DOI 10.1007/s10792-013-9715-9



Your article is protected by copyright and all rights are held exclusively by Springer Science +Business Media Dordrecht. This e-offprint is for personal use only and shall not be self-archived in electronic repositories. If you wish to self-archive your work, please use the accepted author's version for posting to your own website or your institution's repository. You may further deposit the accepted author's version on a funder's repository at a funder's request, provided it is not made publicly available until 12 months after publication.

Prevalence of xerophthalmia among malnourished children in rural Ethiopia

Daniel B. Moore · Wogen Shirefaw ·
Oren Tomkins-Netzer · Zebiba Eshete ·
Hila Netzer-Tomkins · Itay Ben-Zion

Received: 15 November 2012 / Accepted: 5 January 2013
© Springer Science+Business Media Dordrecht 2013

Abstract To assess the prevalence of eye disease among malnourished children in a rural Ethiopian health center and evaluate correlations between xerophthalmia and grades of malnutrition. A retrospective, cross-sectional survey. An institution-based cross-sectional prospective study was performed at Bushulo Health Center in rural south Ethiopia and included all children age 6 months to 14 years receiving care for malnourishment from June 1st to July 30th, 2008. Data collection involved a combination of interviews with caretakers, ocular examination by a pediatric ophthalmologist and anthropometric

measurements. One hundred and seventy-three children (average age at examination 2.9 ± 0.2 years) were treated for malnutrition (97 female, 76 male). One hundred and forty-nine patients had moderate malnutrition (86.03 %) and 24 had severe malnutrition (13.9 %). The following eye diseases were diagnosed—trachoma (12.1 %), blepharitis (13.3 %) and xerophthalmia (20.8 %). Severely malnourished children were more likely to suffer from xerophthalmia than moderately malnourished children ($p < 0.0001$). When comparing anthropometric measurements to the diagnosis of xerophthalmia, only weight percentile showed significance ($p = 0.008$). Xerophthalmia is a common global cause of pediatric blindness and is highly correlated with severe malnutrition. Continued efforts are necessary to improve nutrition and outcomes in these patients.

Keywords Ophthalmology · Malnutrition · Xerophthalmia · Vitamin A deficiency · Ethiopia · International ophthalmology · Anthropometric

D. B. Moore
Duke University Eye Center, Durham, NC, USA

W. Shirefaw · Z. Eshete
Department of Pediatrics, College of Medicine, Hawassa
University, Hawassa, Ethiopia

O. Tomkins-Netzer
Moorfields Eye Hospital, London, UK

O. Tomkins-Netzer
Royal Surrey County Hospital, Guildford, UK

H. Netzer-Tomkins
Department of Pediatrics, Carmel Medical Center, Haifa,
Israel

I. Ben-Zion (✉)
Department of Ophthalmology, Goldschlager Eye
Institute, Shebba, Israel
e-mail: itaybenzion@gmail.com

Introduction

Xerophthalmia describes the ocular manifestations of vitamin A deficiency (VAD) and includes conjunctival and corneal xerosis, keratomalacia, nyctalopia and retinopathy [1]. VAD is a disease largely of the lowest socioeconomic populations in developing countries

where food choices are limited [2]. Malnutrition in children may be a continuation of an undernourished state that began in infancy or it may arise from factors that become operative during childhood. In Ethiopia, the nutritionally inadequate weaning diet and overcooking of limited green leafy vegetables predispose to VAD [3]. A recent survey of third and fourth grade school children in Ethiopia demonstrated the risk of xerophthalmia was comparatively higher in children that had not eaten vegetables or fruits on the day prior to the survey [4].

Xerophthalmia is the leading preventable cause of blindness worldwide and is associated with increased mortality in children 6 months of age and older. Vitamin A supplementation can effectively reduce total mortality in susceptible populations [2, 5, 6]. According to the United Nations Children's Fund, an estimated 84 % of children in Ethiopia aged 6–59 months received at least one high-dose vitamin A capsule in 2010 [7]. However, it is estimated that over 250 million preschool children, largely in developing countries, are at risk of xerophthalmia [8–10].

The purpose of this study is to assess the prevalence of eye disease among malnourished children in a rural Ethiopian health center and evaluate correlations between stages of xerophthalmia and grades of malnutrition.

Methods

An institution-based cross-sectional study was conducted at the Bushulo Health Center outside Hawassa City in rural southern Ethiopia. The hospital is a referral center for an estimated population of 15 million people, with nearly half being children <15 years. This work was part of the ORBIS International and Cyber-Sight project implementing pediatric ophthalmology services in Ethiopia. The study was approved by the Ethical Committee of Hawassa University Health Science College and was in accordance with the Declaration of Helsinki.

All children age 6 months–14 years receiving treatment for malnutrition at Bushulo Health Center from June 1st to July 30th, 2008 were included in a population survey. All children diagnosed with VAD received food supplementation and vitamin A capsules (200,000 IU) at the time of their visit. Children were excluded if they had resided in one of the two local woredas (districts) for <6 months.

Data collection involved a combination of interviews with caretakers, ocular examination and anthropometric measurements. After obtaining informed consent, caretakers were interviewed about the child's gender, age, history of breastfeeding and multivitamin supplementation within 2 weeks of the study period. The eye examination was performed by an experienced pediatric ophthalmologist and included slit-lamp examination and fundus examination using indirect ophthalmoscopy. The presence and severity of xerophthalmia was evaluated on the basis of clinical stages proposed by the WHO [1]. The presence of other eye diseases such as trachoma, blepharitis or infectious corneal diseases was assessed by a pediatric ophthalmologist.

The anthropometric measurements used in the study included weight and height or supine length in children <2 years of age. Body mass index (BMI) and weight-for-height indices were derived from the above measurements. These were all compared to the standard WHO percentile charts according to gender and age, and the percentile for each patient and the distance from the median (z-score) were recorded. Malnutrition was defined as moderate if 2–3 SD and severe if >3 SD below the median of the weight-for-height percentile [11].

Statistical analysis was performed using SPSS (version 13, SPSS Inc., IL, USA). All results are presented as the mean \pm SEM.

Results

One hundred and seventy-three children suffering from malnutrition (97 female, 76 male) were included. The mean age at examination was 2.9 ± 0.17 years. A total of 149 patients were found to have moderate malnutrition (86.0 %) and 24 were diagnosed with severe malnutrition (13.9 %). Ninety children had a normal eye examination (52.0 %). The remaining children had the following conditions: trachoma (13.3 %, $n = 23$), blepharitis (17.3 %, $n = 30$) and xerophthalmia (20.8 %, $n = 36$) (Fig. 1). Females were more likely to have xerophthalmia than males (26.8 vs 13.2 %, respectively, $p = 0.028$, Pearson's Chi squared test), and they accounted for the majority of diagnosed cases (72.2 %, $n = 26$). Severely malnourished children were more likely to suffer from any ocular disease than moderately malnourished children

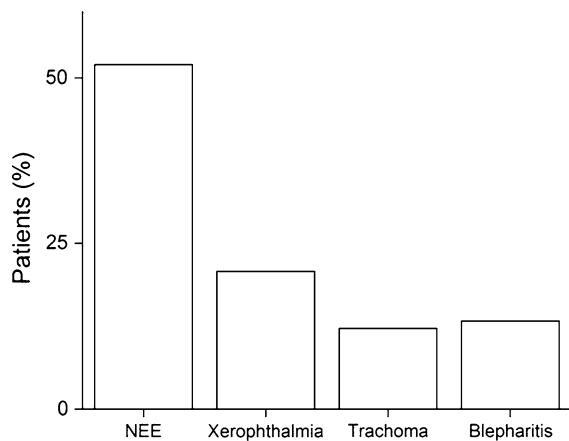


Fig. 1 Findings among children that underwent eye examination ($n = 173$). *NEE* normal eye examination

(66.7 vs 43.0 %, respectively, $p = 0.026$, Pearson's Chi squared test). Specifically, they were more likely to suffer from xerophthalmia than moderately malnourished children (50.0 vs 16.1 %, respectively, $p < 0.0001$, Pearson's Chi squared test) (Fig. 2).

When examining BMI, weight, height and weight-height ratio compared to the presence or absence of xerophthalmia, only weight percentile showed significance (2.7 ± 1.5 vs 10.0 ± 2.2 %, $p = 0.008$). When correlations were examined regarding ocular disease in general, no differences were noted (data not shown).

Discussion

Xerophthalmia, a disease resulting from VAD, is the most common global cause of childhood blindness, resulting in roughly 350,000 new cases every year [12]. Despite its high incidence, there is a low prevalence of xerophthalmia in the developing world. This is explained by the high mortality rate of these children; the majority of children with VAD significant enough to result in corneal ulceration die within the first year of life [5]. In this study, we examined the prevalence of xerophthalmia among Ethiopian children suffering from malnutrition and found that (1) approximately 50 % of children suffered from ocular disease; (2) xerophthalmia affected one in five malnourished children; (3) children with xerophthalmia were found to be at a lower weight percentile; and (4) risk factors associated with xerophthalmia included female gender and a state of severe malnutrition.

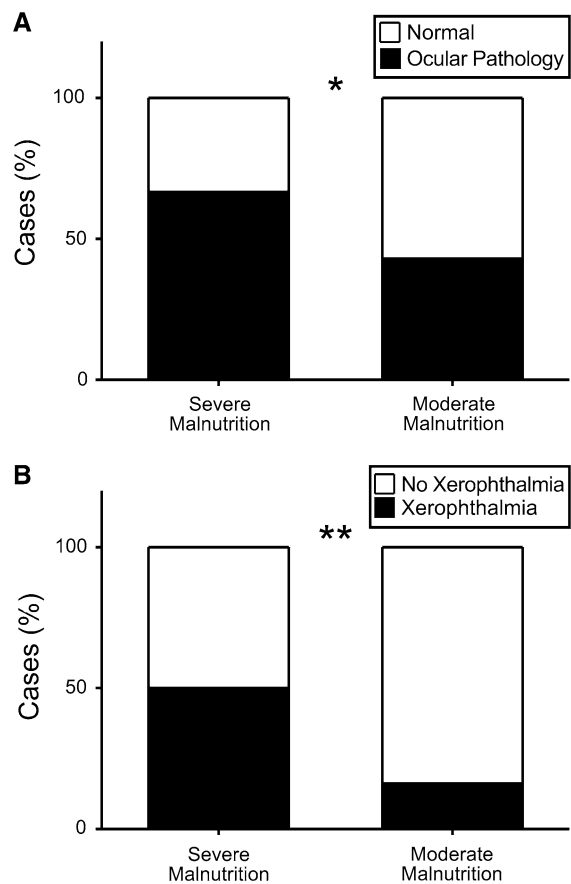


Fig. 2 **A** Comparative rates of normal eye examination (NEE) ($n = 90$) versus ocular pathology ($n = 83$) in patients with severe or moderate malnutrition. **B** Comparative rates of the presence ($n = 36$) or absence ($n = 137$) of xerophthalmia in patients with severe or moderate malnutrition

VAD has protean clinical manifestations, but the presence of xerophthalmia is essentially pathognomonic [5]. Vitamin A serves two fundamental purposes in ocular health. In the retina, it functions as a precursor to photosensitive pigments involved in the stimulation of the visual pathway. It is also essential to epithelial differentiation and proliferation in the conjunctiva and cornea. As such, xerophthalmia manifests as nyctalopia, conjunctival and corneal xerosis, corneal ulceration, keratomalacia and corneal scars [13].

The first randomized trial evaluating the effect of vitamin A supplementation on child mortality was undertaken in Indonesia and published in 1986 [6]. The impressive results, a 34 % reduction in mortality amongst 1- to 5-year-olds, were met with some

resistance, yet the majority of subsequent major trials documented similar findings [5]. Most of the prevented deaths were thought secondary to less severe manifestations and complications associated with measles and diarrheal diseases in children receiving vitamin A supplementation [14]. Due largely to the efforts of these pioneers, more than 70 countries now have national programs addressing VAD and vitamin A 'coverage' has become one of the core health indicators published annually in the State of the World's Children. UNICEF estimates that every year, over half a billion vitamin A capsules are distributed and prevent roughly 350,000 childhood deaths [5].

Despite these encouraging results, VAD remains a significant cause of morbidity and mortality among certain developing world populations. A 1980–81 national survey in Ethiopia found that roughly 60 % of children <6 years of age suffered from subclinical VAD (serum retinal level <0.70 $\mu\text{mol/l}$) [9]. A more recent survey in Wukro, north Ethiopia, documented almost identical results in children aged 6–9 years [15]. The prevalence of xerophthalmia in the aforementioned reports was 6 and 5.8 %, respectively.

In this study, we demonstrate a 20 % prevalence of xerophthalmia among malnourished children presenting for medical attention in south Ethiopia. The majority of these patients were female, which is dissimilar from other studies. This finding is unlike prior studies that showed either male predominance [15] or equal rates [4]. It was suggested this may in part be explained by the observations that boys are more prone to diarrheal illnesses and girls tend to aid in food preparation and therefore are more likely to have access to vitamin A-enriched foods [16]. The reasons for the female preponderance in the current study are likely multifactorial. Reports of other pediatric eye diseases from Africa have found a significant difference in the length of delay between boys and girls as well as treatment outcomes, both favoring the male gender. This seems to have more to do with the socioeconomic role of gender, rather than any biological predisposition [16–20]. Similar to these studies, most of our patients are from rural African tribes, where social etiquette favors the male gender, which may mean that food is less available to females, leading to higher rates of malnutrition. Furthermore, given the young age of patients in this study (mean 2.9 years), females were unlikely to participate in meal preparation and have preferential access to enriched foods.

As xerophthalmia is a manifestation of vitamin A deficiency, malnutrition has been closely linked to the disease [21]. We found that children suffering from severe malnutrition were much more likely to have xerophthalmia than those that were moderately malnourished. Furthermore, we found that lower weight percentile was significantly correlated with the presence of xerophthalmia. It is interesting to note that there was no association with BMI, height or weight-height. Malnutrition typically presents first with lower weight and only later lead to stunting of height [22]. Xerophthalmia may therefore correlate better with such early changes. It is possible that a larger population sample or a long-term prospective study will confirm these associations.

Many of the consequences of VAD are potentially avoidable, and three major preventative plans have been suggested—(1) routine high-potency vitamin A supplementation; (2) fortified foods; and (3) improving the availability of vitamin A-rich foods [23]. Breast milk is an excellent source of vitamin A and other nutrients and needs to be emphasized as an important aspect in prevention. Mothers also need education on proper weaning diets [24]. Much of the current success combating VAD is a result of integration of vitamin A supplementation programs with other health care measures such as measles vaccination, nutrition screening, deworming, educational programs on breastfeeding and the distribution of iodized oil supplements [25]. In regions such as south Ethiopia, vitamin A-containing foods are scarce and expensive. Public health efforts to fortify foods used in the common diet have recently been advocated, with a trial of maize biofortification in sub-Saharan Africa demonstrating some promising early results [24, 26].

There are several limitations to this study. It was conducted at a single location and patients were all presenting for evaluation of malnutrition. This suggests our findings are likely an under-representation of the total pediatric population in south Ethiopia. Indeed, Scheman et al. [16] found that increasing distance to the nearest medical center was significantly correlated to the presence of xerophthalmia. There was a relatively small sample size, no follow-up was available and the data was collected over a short period of time during the dry months, possibly misrepresenting yearly seasonal fluctuations. Further studies will be needed to confirm these findings.

Xerophthalmia is a manifestation of VAD and remains the most common cause of pediatric blindness worldwide. In parts of the developing world such as Ethiopia, it is highly correlated with malnutrition and underweight children, and those at risk need careful eye examinations to further evaluate for potential blinding disease. Continued global efforts are necessary to improve nutrition and outcomes in these patients.

Financial Support This work was sponsored in part by the ORBIS International and Cyber-Sight project implementing pediatric ophthalmology services in Ethiopia.

Conflict of interest No conflicting relationship exists for any author.

References

1. WHO. Vitamin A deficiency and xerophthalmia. Report of a joint WHO/USAID meeting. WHO Technical Report Series 590. Geneva: WHO;1976. pp. 1–88
2. Sommer A, West KP Jr (1996) Vitamin A deficiency: health, survival, and vision. Oxford Press, New York
3. Underwood BA, Osen JA ed. Introduction. In: A brief guide to current methods of assessing vitamin A status. A report of International Vitamin A Consultative Group (IVACG); 1993
4. Hall A, Kassa T, Demissie T et al (2008) National survey of the health and nutrition of schoolchildren in Ethiopia. *Trop Med Int Health* 13:1518–1526
5. Sommer A (2008) Vitamin A deficiency and clinical disease: an historical overview. *J Nutr* 138:1835–1839
6. Sommer A, Tarwotjo I, Djunaedi E et al (1986) Impact of vitamin A supplementation of childhood mortality: A randomized controlled community trial. *Lancet* 1:1169–1173
7. The World Bank. Vitamin A supplementation coverage rate (% of children ages 6–59 months). <http://data.worldbank.org/indicator/SN.ITK.VITA.ZS>. Accessed 8 Feb 2012
8. Underwood BA, Arthur P (1996) The contribution of vitamin A to public health. *FASEB J* 10:1040–1048
9. Wolde-Gebriel Z, Demeke T, West CE (1991) Xerophthalmia in Ethiopia: a nationwide ophthalmical, biochemical, anthropometric survey. *Eur J Clin Nutr* 45:469–478
10. Asrat YT, Omwega AM, Muita JW (2002) Prevalence of vitamin A deficiency among pre-school and school-aged children in Arssi Zone. Ethiopia. *East Afr Med J* 79: 355–359
11. WHO Multicentre Growth Reference Study Group (2006) WHO Child Growth Standards: Length/height-for-age, weight-for-age, weight-for-length, weight-for-height and body mass index-for-age: Methods and development. World Health Organization, Geneva
12. Whitcher JP, Srinivasan M, Upadhyay MP (2001) Corneal blindness: a global perspective. *Bull World Health Organ* 79:214–221
13. Smith J, Steinemann T (2000) Vitamin A deficiency and the eye. *Int Ophthalmol Clin* 40:83–91
14. Glasziou PP, Mackerras DEM (1993) Vitamin A supplementation in infectious diseases: a meta-analysis. *BMJ* 306:366–370
15. Kassaye T, Receveur O, Johns T et al (2001) Prevalence of vitamin A deficiency in children aged 6–9 years in Wukro, northern Ethiopia. *Bull World Health Organ* 79:415–422
16. Schemann JF, Malvy D, Zefack G et al (2007) Mapping xerophthalmia in Mali: results of a national survey on regional distribution and related risk factors. *J Am Coll Nutr* 26:630–638
17. Ben-Zion I, Tomkins O, Moore DB, Helveston EM (2011) Surgical results in the management of advanced primary congenital glaucoma in a rural pediatric population. *Ophthalmology* 118(231–5):e1
18. Bowman RJC, Dickerson M, Mwende J et al (2011) Outcomes of goniotomy for primary congenital glaucoma in East Africa. *Ophthalmology* 118:236–240
19. Waddell KM (1998) Childhood blindness and low vision in Uganda. *Eye* 12:184–192
20. Yorston D, Wood M, Foster A (2001) Results of cataract surgery in young children in east Africa. *Br J Ophthalmol* 85:267–271
21. Lemma F, Mariam AG (1996) Xerophthalmia and malnutrition among pre-school children in Agaro town south-west Ethiopia. *East Afr Med J* 73:179–181
22. Bhagowalia P, Chen SE, Masters WA (2011) Effects and determinants of mild underweight among preschool children across countries and over time. *Econ Hum Biol* 9:66–77
23. West KP Jr, McLaren D (2003) The epidemiology of vitamin A deficiency disorders. In: Johnson GJ, Minassian DC, Weale RA, West SK (eds) *The Epidemiology of Eye Disease*, 2nd edn. Oxford University Press, New York
24. Sherwin JC, Reacher MH, Dean WH et al (2012) Epidemiology of vitamin A deficiency and xerophthalmia in at-risk populations. *Trans Roy Soc Trop Med Hyg* 106:205–214
25. UNICEF. Tracking progress on maternal and child nutrition: A survival and development priority. New York: UNICEF;2009
26. Muzhingiri T, Gadaga TH, Siwela AH et al (2011) Yellow maize with high (beta)-carotene is an effective source of vitamin A in healthy Zimbabwean men. *Am J Clin Nutr* 94:510–519